

Application of Buccal Mucosa in Secondary Hypospadias Repair

HESHAM EL-SAKET, M.D.**; ALI ZIADA, M.D.* and KHALED MAKEEN EL-RIFAIE, M.D.**

*The Departments of Surgery** and Urology*, Faculty of Medicine, Cairo University.*

ABSTRACT

Objectives: We report our experience in using buccal mucosa for repair of hypospadias in complicated and crippled patients who underwent one or more previous failed attempts at repair.

Methods: During the period between January 1998 and June 2002, 24 children of different age groups with recurrent hypospadias presented to our hospital for repair. The site of the meatus ranged from midpenile to perineal. The age ranged from 1.5 years to 7 years. All the patients were followed up at 1 wk, 3 wks, 6 wks, 3 months and 6 months. These patients had multiple previous attempts at repair ranging from 2 to 5 times. The harvest site of the buccal mucosa was the cheek in 16 cases and the lower lip in 8 cases depending on the length required. The distance to be bridged ranged from 1.5 cm to 6 cm.

Results: The follow up ranged from 4 to 24 months with mean follow up of 18 months. Only 2 patients developed complications at the graft donor site in the form of contraction. One case involved the lower lip required no intervention while the other case involving the cheek donor site required subsequent release by Z-plasty. Nine patients developed complications of the urethroplasty; meatal stenosis developed in 2 patients in the distal half centimeter of the graft. One of those patients improved with regular dilatation under general anesthesia while the other was successfully revised. Urethrocutaneous fistula occurred in 4 patients. Two patients developed a urethral stricture, one at the site of the proximal anastomosis and the other at mid-urethra. Of those 2 patients, one was successfully managed with internal urethrotomy whereas the other required surgical repair with no graft required. Graft failure with complete disruption occurred in two patients.

Conclusion: The cosmetic and functional results were both very good. The success rate was 62%.

INTRODUCTION

Urethral reconstruction is required in congenital anomalies whether epi- or hypospadias and also in cases of urethral strictures. In the majority of cases, local penile and preputial skin is sufficient for repair. Inadequate genital tissue present has been a hindrance for urethral recon-

struction. Local tissue is usually inadequate to provide skin cover as well as construct the neourethra after previous attempts at surgical repair resulted in loss of tissue and scar formation. It is also encountered, rarely, in severe hypospadias. The lack of tissue resulted in surgeons contemplating the use of free tissue grafts for neourethral reconstruction [1].

Initial attempts using full thickness skin grafts from non hair-bearing sites provided a reasonable success rate. The skin grafts carried the risk of graft shrinkage, stricture formation, balanitis xerotica obliterans and scar formation at the donor site. The long-term results proved unsatisfactory [2].

Alternatively, bladder mucosa was described for urethral replacement. While this technique became quite popular, it suffered from two major disadvantages: the need for a cumbersome separate incision procedure for harvesting besides the tendency to prolapse from the meatus, which is known as the cauliflower deformity [3].

Humby, in 1941, first suggested the use of buccal mucosa for urethral replacement. Duckett in 1986 reported on using buccal mucosal graft from the cheek in the repair of epispadias or subsequently in complex hypospadias redo operations and in urethral strictures. Buccal mucosa has advantages over both skin and bladder grafts. The thick epithelial layer, abundant elastic fibres, less tendency to shrink and favorable imbibition properties make it more suitable for neourethral reconstruction [6,7,8].

The aim of our work was to evaluate the use of buccal mucosa for urethral reconstruction in recurrent hypospadias and study the incidence and severity of complications both to the donor and recipient sites.

MATERIAL AND METHODS

From 1998 to 2002, 24 patients underwent urethral reconstructions using a buccal mucosal graft at The Children's Hospital of Cairo University. Patients' age ranged from 1.5 to 9 years. All patients had previous unsuccessful repair of hypospadias (Table 1).

Preparation of the recipient bed:

In all cases, proper examination of the penis was performed at the start of the procedure. Artificial erection was done to properly evaluate the degree of curvature. Care was taken to ensure removal of scar tissue and strictured segments of the urethra to allow for a vascularized graft bed. Wide glans wings or sometimes comprehensive dissection and excision of the glans was employed to prevent stricture and stenosis at the distal anastomotic site. The remaining part of the native urethra was adequately spatulated back to vascularized tissue for the proximal anastomosis.

Technique of harvest of the buccal mucosa (Fig. 1):

Donor sites for buccal mucosal grafts included inner lower lip in 8 cases and inner cheek in 16 cases. The required length determined the choice of donor site. The inner cheek was used when the required graft exceeded 4 cms. Buccal mucosal harvesting followed the standard techniques in the literature [9,10]. Lidocaine (1%), pre-mixed with adrenaline (1:100,000) is injected along the lateral borders of the graft side for hemostasis before the incision. The harvest site was marked carefully to avoid Stensen's duct, opposite the upper second molar when harvesting from the inner cheek. To assist Stensen's duct identification, compression was applied to the parotid gland. Dissection was carried down to the palate. The buccinator muscle was left in situ. The buccal mucosal graft is immersed in saline to which penicillin and gentamycin have been added. The graft is then thinned and tabularized over a catheter, the size of which depends on the age of the patient. Absorbable sutures were used for closure of the donor site in case of the inner cheek whereas healing by secondary intention was allowed for inner lower lip graft sites to prevent contractures. After the harvested mucosa was acquired, it was cleared from excess fat to have the mucosa and submucosa. The urethroplasty was performed using 5-0 and 6-0

vicryl continuous sutures with interrupted sutures at the ends. The tubed graft was fixed to the corporal bodies to prevent kinking. The graft suture line is placed dorsally against the corpora to diminish the risk of fistula formation [11].

In scrotal and perineal types, the pretesticular tissues on both sides were approximated in the midline to add more protective tissue to the proximal anastomosis. A vascularized tunica vaginalis flap was wrapped around the neourethra to add an additional protective covering layer over the whole reconstructed tube.

Postoperative care:

Postoperative care for buccal mucosal grafts included adequate urinary diversion to allow the healing of the delicate graft. All urethroplasties were stented for 2 weeks. In all cases, a suprapubic tube was used. The patients were kept on antibiotics for the duration of the indwelling catheter. A subcutaneous suction drain was left for 12 hours, adjacent to the neourethra, to prevent hematoma formation after which a compressive occlusive dressing was used. The dressing was removed on day 5 to day 7, changed every 2 days with lavage of the neourethra using antibiotic solution (gentamycin and crystalline penicillin or piperacillin) through the urethral stent. Older children were instructed to minimize their activity to assure graft immobilization. Amyl nitrate was also used in older children in the early postoperative period to control erections. Most patients stayed in the hospital for 48 hours. A clear liquid diet was given initially then rapidly advanced to a soft then regular diet. Meatal dilatation was used after catheter removal for up to 6 months to avoid stenosis, patient was instructed for visits once weekly in the first month, then once monthly in the following 6 months, then every 3 months.

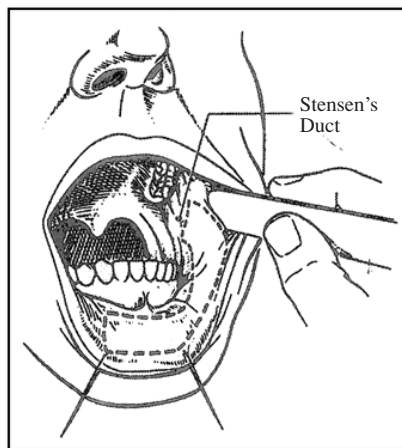
RESULTS

The follow up ranged from 4 to 24 months with a mean follow up of 18 months. The donor sites for the buccal mucosal grafts included the inner lower lip in 8 cases and inner cheek in 16 cases. Only 2 patients developed complications at the graft donor site. One patient developed a scar contracture of a cheek donor site that had been primarily closed. This required subsequent release by Z-plasty. The second patient developed a mild scar contracture at the end of the lower

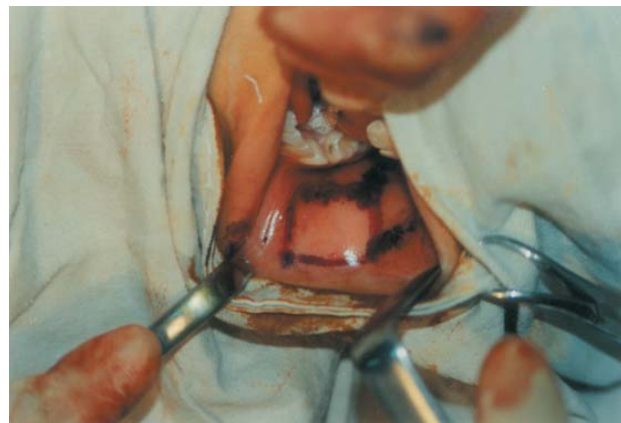lip donor site that had been part of a long graft starting at the cheek and extending into the lower lip. This progressively resolved and did not require revision.

Of the 24 patients, nine developed complications of the urethroplasty. Two patients developed meatal stenosis in the distal half centimeter of the graft. This resulted in mild proximal urethral dilatation. One of those patients improved with regular dilatation under general anesthesia while the other was successfully revised. Four patients

developed a urethrocutaneous fistula, three of these occurring at the proximal anastomosis. Of the four, two were successfully repaired with primary closure while the other two are currently awaiting repair. Two patients developed a urethral stricture, one at the site of the proximal anastomosis and the other at mid-urethra. Of those 2 patients, one was successfully managed with internal urethotomy whereas the other required surgical repair with no graft required. Graft failure with complete disruption occurred in two patients.



(A)



(B)

Fig. (1: A,B): Harvest site for buccal mucosa (Brock, 1995).

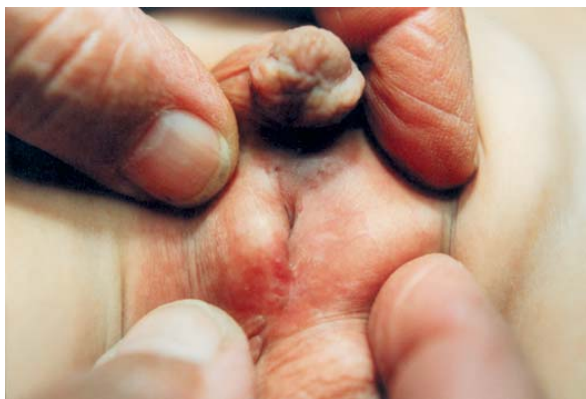

Fig. (2): Hypospadias of one of the patients of the study.

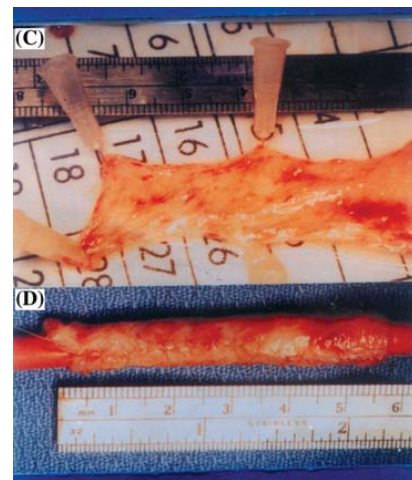


Fig. (3): Harvested buccal mucosa.

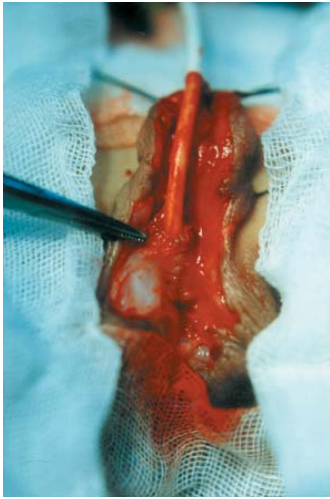

Fig. (4): Anastomosis of the buccal mucosal tube to the urethral meatus.

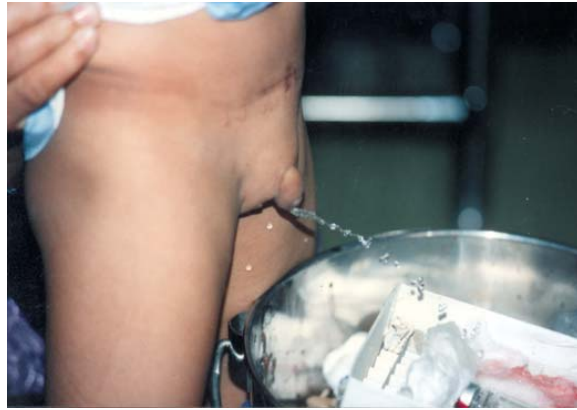

Fig. (5): Final result showing good urinary stream following correction.

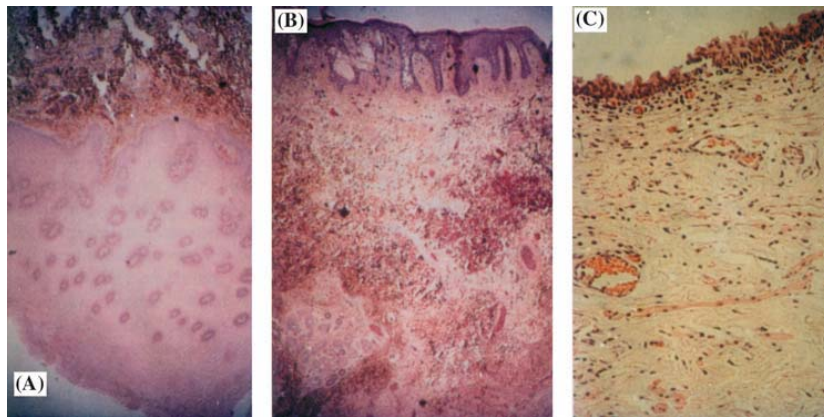


Fig. (6): Micrograph of buccal mucosal graft.

A: Skin graft of penile skin.

B,C: Buccal mucosa with thick epithelial layer with more cell layers compared to penile skin. Lamina propria of the buccal mucosa is much thinner than the dermis of penile skin (H & E reduced from x 100).



Fig. (7): Immunofluorescence stain for type IV collagen reveals dense plexus of blood vessels immediately below basement membrane in buccal mucosa.

Table (1): Summary of preoperative data and outcome of patients included in the study.

	Age (Y)	Last previous operation done	Of repairs	Site of meatus	Length of harvest	Site of harvest	Complications
1	4.5	Bladder mucosal graft	5	Penoscrotal	5 cm	Cheek	Contracture scar of cheek Z plasty
2	3	Onlay graft	4	Perineal	5.5 cm	Cheek	Severe infection γ complete failure
3	3	Bladder mucosal graft	5	Post. Penile	4.5 cm	Cheek	
4	2	Transverse preputial flap	3	Post. Penile	4 cm	Cheek	Fistula
5	2.5	Onlay graft	3	Midpenile	3 cm	Lip	
6	3	Onlay graft	3	Midpenile	2.5 cm	Lip	Stricture + meatal stenosis
7	5	Transverse preputial flap	5	Penoscrotal	6 cm	Cheek	Fistula
8	4	Onlay graft	4	Post. Penile	5 cm	Cheek	
9	3	Onlay graft	2	Midpenile	1.5 cm	Lip	Severe infection γ complete failure
10	2	Transverse preputial flap	3	Post. Penile	3.5 cm	Lip	Mild infection + fistula
11	6	Onlay graft	4	Penoscrotal	5.5 cm	Cheek	
12	5	Onlay graft	3	Post. Penile	4 cm	Cheek	Mild contracture scar lower lip
13	2	Transverse preputial flap	2	Midpenile	1.5 cm	Lip	Stricture
14	6	Transverse preputial flap	5	Post. Penile	5.5 cm	Cheek	
15	6	Transverse preputial flap	3	Post. Penile	4.5 cm	Cheek	Meatal stenosis
16	3	Onlay graft	3	Midpenile	2.5 cm	Lip	Fistula
17	2	Onlay graft	4	Perineal	6 cm	Cheek	
18	4	Transverse preputial flap	2	Midpenile	3.5 cm	Lip	Fistula
19	3	Onlay graft	2	Penoscrotal	6 cm	Cheek	
20	4	Onlay graft	3	Post. Penile	4.5 cm	Cheek	
21	2	Transverse preputial flap	2	Midpenile	3 cm	Lip	
22	7	Transverse preputial flap	4	Midpenile	4.5 cm	Cheek	
23	1.5	Onlay graft	2	Post. Penile	5 cm	Cheek	
24	2.5	Onlay graft	3	Perineal	5.5 cm	Cheek	Contracture scar of cheek γ Z plasty

DISCUSSION

Several tissue choices are available to reconstructive surgeons faced with the need to reconstruct the urethra especially after several previous attempts at repair resulted in lack of available genital tissue. The results vary depending on the characteristics of different tissues. Full-thickness skin grafts have been used but follow-up demonstrated problems with graft contracture, stricture formation along with development of balanitis xerotica obliterans in some cases. Urologists turned to bladder mucosa, reporting early success, but again longer follow-up decreased the enthusiasm due to relative complexity of harvesting the graft as well as development of tissue exuberance at the meatus causing splaying the stream at stenosis as well as sticky meatus. Humby [4] first suggested buccal mucosal use in 1941, but the technique was not made popular until the 1980's. This was the result of publication of several series with low complications rate considering the technical difficulty of the required repair, which in the majority of cases has previously failed. Burger et al. [11] used buccal mucosa in 6 cases (4 tubed and 2 patch), resulting in 3

fistulas and a single case of meatal stenosis. Dessanti et al. [8] reported using buccal mucosa in 8 cases (5 cases were combined bladder and buccal mucosa). They reported one case of fistula and 2 anastomotic stenosis. Baskin and Duckett [10] reported on 30 urethral reconstructions with a 20% reoperation rate. They had 3 cases of meatal stenosis and 3 cases of fistula [12].

Comparing the histologic characteristics of skin, bladder and buccal grafts showed that buccal mucosa has a very thick epithelial layer and a thin lamina propria. The thick epithelial layer may account for the mechanically stiff characteristics of buccal mucosal grafts. Elastic fibres have also been shown to be more abundant in buccal grafts that may explain its resilience. Compared to bladder mucosal grafts, buccal mucosa has less tendency to shrink and can hence be harvested and prepared for use in a 1:1 ratio with the defect to be bridged. Furthermore, immunohistochemical staining of the buccal mucosa with an antibody to type IV collagen reveals that the lamina propria is rich with vascular structure allowing more efficient angiogenesis between the donor and recipient site. This

may account for the excellent take of buccal mucosal grafts. The thin lamina propria also may allow imbibition to occur more efficiently, hence, the importance of fat removal during preparing the graft.

The buccal and bladder mucosal grafts lack the support of the corpus spongiosum leading to ballooning of the neourethra. Theoretically, the stiffness and elasticity of the buccal mucosa should result in less diverticulum formation. One of the major advantages of buccal mucosa over bladder mucosa and skin is that the supply source is constant and adequate as well as the ease of harvesting without leaving a cosmetically compromised donor site [13].

This series is similar to others in the results and variety of complications. The overall urethral complication rate was 9 cases (62%). Some of the complications were handled with a single simple reoperation (fistulae), which is acceptable considering the complexity of each case. While 2 patients developed meatal stenosis, it is noteworthy that there were no cases of meatal prolapse of mucosa commonly seen with the use of bladder mucosa. The 2 cases of graft failure (8%) were due to severe postoperative infection.

The inner cheek was the preferred donor site for buccal mucosal graft due to thicker epithelium, more flexibility and surface area than the lip mucosa. Only 2 cases reported complications in the donor site but only one required intervention. We report no cases of infection or injury to the parotid duct.

Conclusion:

The buccal mucosa provides an attractive source of graft material in cases of urethral reconstruction with lack of genital skin as a result of previous failed repair. The buccal mucosa is easily harvested with few side effects on the donor site. The characteristics of the graft such as elasticity, thick mucosa, vasculature and

tolerance to exposure appear ideal for urethral replacement. Our results with this technique were satisfactory with the complication rates acceptable in comparison with the literature.

REFERENCES

- 1- Ransley P.G., Duffy P.G. & Van Oyen P.: The use of bladder mucosa and combined bladder mucosa, preputial skin Haps for urethral reconstruction. *J. Urol.*, 138: 1097, 1987.
- 2- Webster G.D., Brown M.W., Koefoot R.J. and Sihelnick S.: Suboptimal results in full thickness skin graft urethroplasty using an extrapenile skin donor site. *J. Urol.*, 131: 1082-3, 1984.
- 3- Keating M.A., Cartwright P.C. and Duckett J.W.: Bladder mucosa in urethral reconstruction. *J. Urol.*, 144: 827-34, 1990.
- 4- Humby G.A.: A one-stage operation for hypospadias. *Br. J. Surg.*, 29: 84-92, 1941.
- 5- Duckett (Thesis p. 60), 1986.
- 6- Duckett J.W., Coplen D., Ewalt D. and Baskin L.: Buccal mucosa in urethral replacement. *J. Urol.*, 153: 1660-3, 1995.
- 7- Coleman J.W.: The bladder mucosal graft technique for hypospadias repair. *J. Urol.*, 125: 708-710, 1981.
- 8- Dessanti A., Rigamonti W., Merulla V., Falchetti D. and Caccia G.: Autologous buccal mucosa graft for hypospadias repairs: an initial report. *J. Urol.*, 147: 1081-4, 1992.
- 9- Morey A.F. & McAninch J.W.: Technique of harvesting buccal mucosa for urethral reconstruction. *J. Urol.*, 155 (5): 1696-7, 1996.
- 10- Baskin L.S. and Duckett J.W.: Buccal mucosal grafts in hypospadias surgery. *Br. J. Urol.*, 76 (Suppl. 3): 23-30, 1995.
- 11- Burger R.A., Muller S.C., El-Damanhoury H., Tschakaloff A., Reidmiller H. and Hohenfellner R.: The buccal mucosal graft for urethral reconstruction: a preliminary report. *J. Urol.*, 147: 662-664, 1992.
- 12- Decter R.M., Roth D.R. and Gonzales R.J.: Hypospadias repair by bladder mucosal grafts an initial report. *J. Urol.*, 150: 1256-8, 1988.
- 13- Brock J.W.: Autologous buccal mucosal graft for urethral reconstruction. *Urol.*, 44 (5): 753-55, 1995.